

# The Midline Approach for Lumbar Discectomy

Jun-Hyeok Song, Young Soo Kim

## Introduction

Lumbar microdiscectomy for disc herniation is one of the most common operations performed by spinal surgeons. Since Mixter and Barr described their clinical series on surgically treated patients with sciatica in 1934, numerous authors have refined the technique to achieve maximal surgical benefits with low complication rate. Although it appears to be a simple and unchallenging operation, it does have pitfalls. The goal of this chapter is to describe the standard technique and the pertinent anatomy in lumbar disc surgery.

## Anesthesia

The choices of anesthesia for lumbar microdiscectomy are local, epidural, spinal and general anesthesia. The authors

prefer epidural anesthesia with intravenous sedation.

## Patient Positioning and Marking

There are three choices to position patients: prone kneeling, prone and lateral decubitus. The patient is generally positioned prone with the spine flexed to aid intraoperative exposure of the interlaminar space. Abdominal compression is avoided by properly positioning the patient on a frame or rolls to reduce intraoperative venous bleeding (Figure 40-1).

The level to receive surgical intervention should be marked before prepping and draping. We routinely use C-arm fluoroscopy to identify the disc level of interest. A 23-gauge spinal needle is inserted into the paraspinal muscle approximately 1.5 cm lateral to the midline, at the appropriate disc level. The needle is repositioned until it is directly over

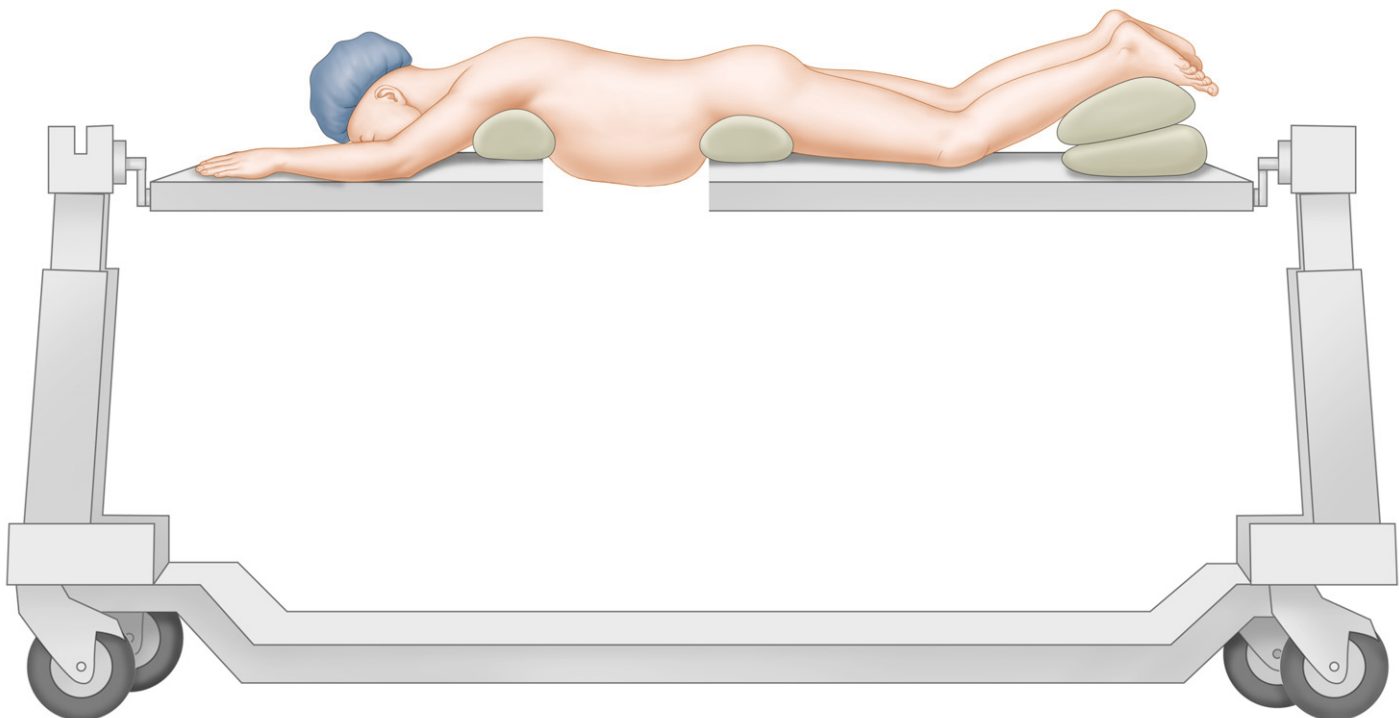


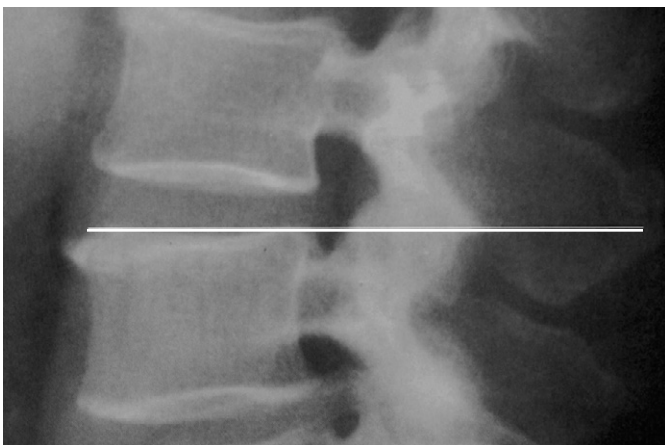Figure 40-1. An example of the prone position on the frame and roll.

the inferior edge of the disc space (Figure 40-2). Subsequently, the patient's back is washed and draped in standard surgical fashion.

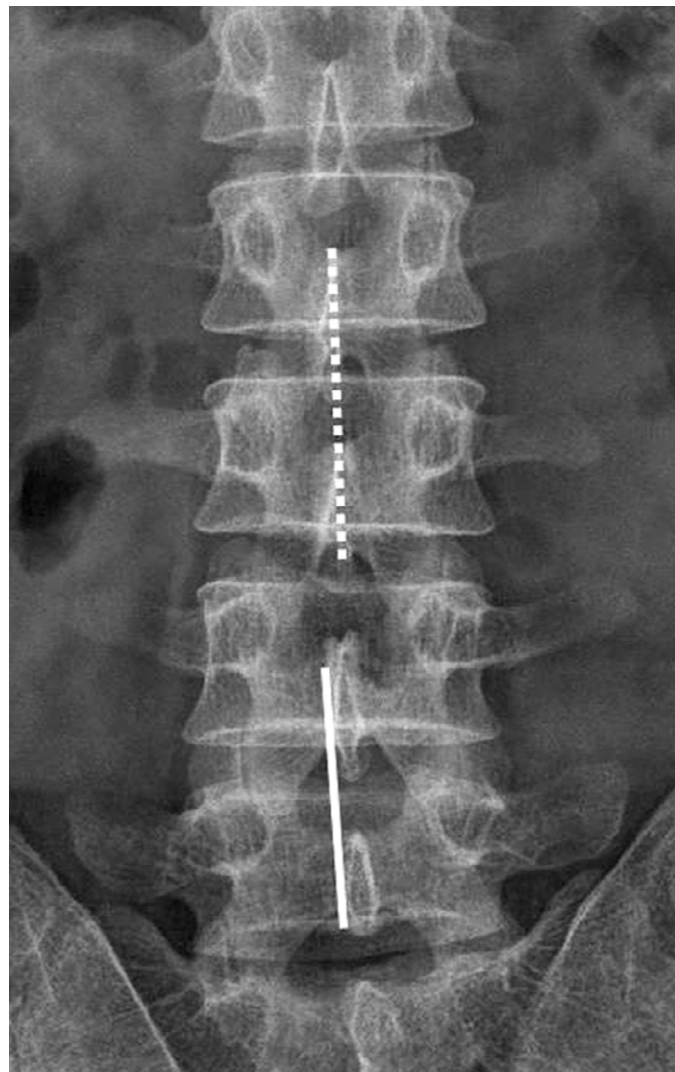
## Skin Incision and Exposure of the Interlaminar Space

The skin incision, 1/2 inch to 1.5 cm on either side of the marking line, is made beside the spinous process, rather than in the midline (Figure 40-3). When subtotal laminectomy or bilateral laminotomy is required, the incision lies on the midline. The skin opening and fascial incision are designed to cause the least amount of damage to the interspinous-supraspinous ligament complex. The paravertebral fascia is incised with an electrocautery from its midline attachment to

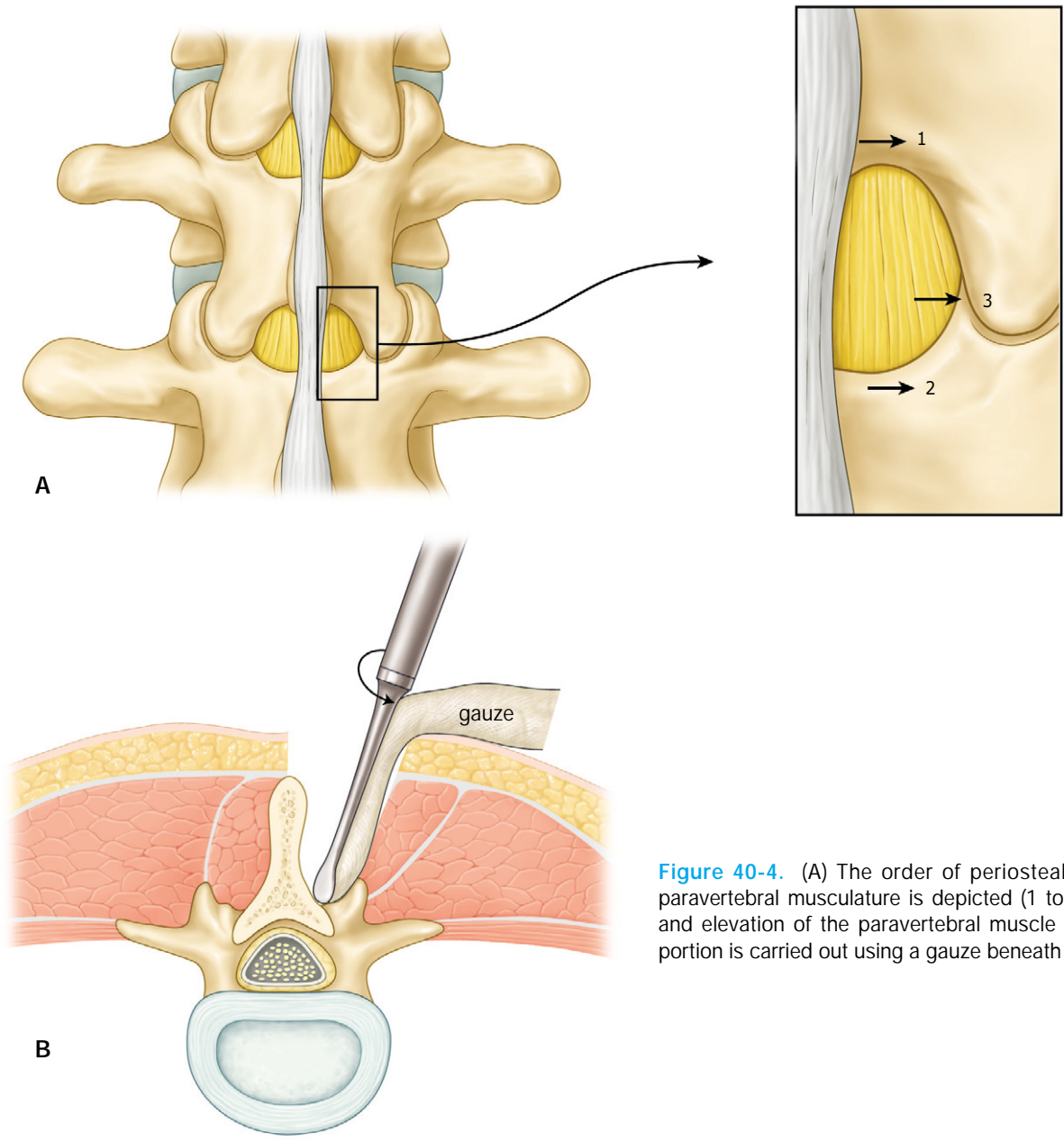
the appropriate spinous process. A periosteal elevator is inserted into the fascial opening and directed towards the midline. Gentle lateral movements are used to separate the paravertebral muscles from the spinous process and lamina. Subperiosteal dissection of the paravertebral muscular tendinous attachments is carried out using a combination of electrocautery and dissection with a curved periosteal elevator (Figure 40-4). For simple disc excision, all that needs to be exposed is the interlaminar interval and a small amount of the lamina on either side. If wider decompression is needed, muscle dissection and laminectomy needs to be extended accordingly (Figure 40-5). A commercially designed microdissectomy retractor, or Taylor retractor is inserted into the wound to retract the paravertebral muscle. Overhanging superficial fascia, fat and any bulbous spinous process that interferes with the surgeon's line of vision should be removed.



**Figure 40-2.** The marking should aim at the inferior edge of the disc.

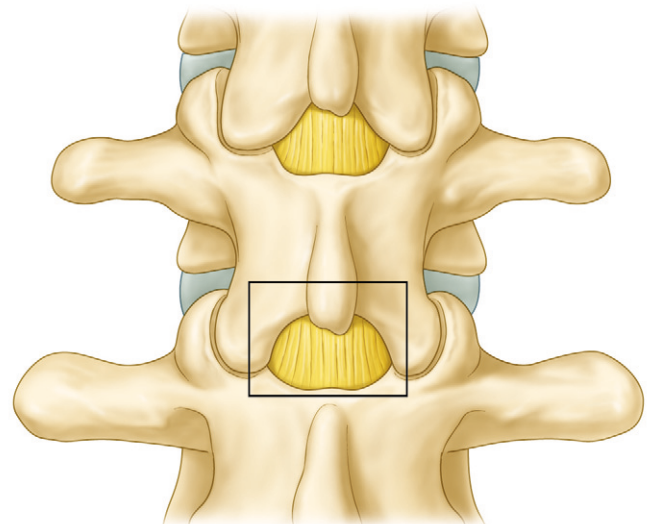


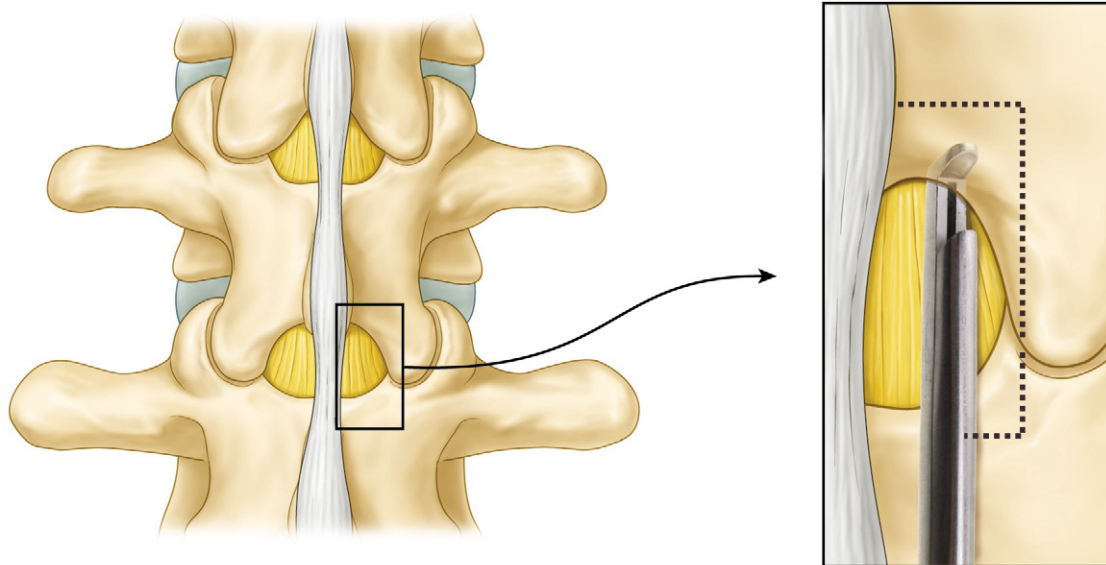
**Figure 40-3.** The skin incision line lies just off the midline on the symptomatic side (straight line). In case of the subtotal laminectomy or bilateral laminotomy, the line is in the midline (dotted line).



**Figure 40-4.** (A) The order of periosteal elevation of the paravertebral musculature is depicted (1 to 3). (B) Retraction and elevation of the paravertebral muscle and its tendinous portion is carried out using a gauze beneath an elevator.

**Figure 40-5.** In case of a huge disc herniation, subtotal laminectomy may be required. The range of the bone removal is shown in the box.



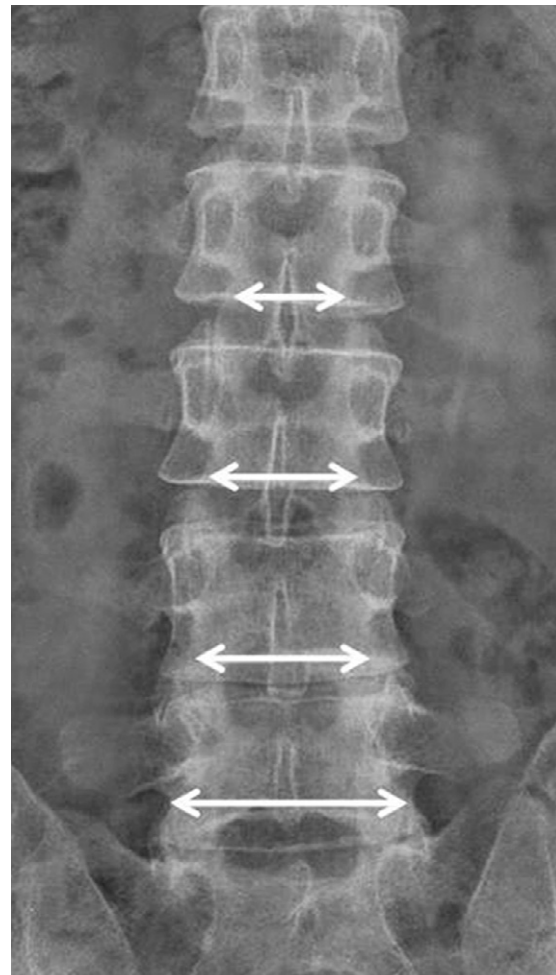


**Figure 40-6.** The lamina is removed using a Kerrison punch. The borders for laminar removal is the midline recess of the yellow ligament superiorly, and the down-going slope of the ligament laterally.

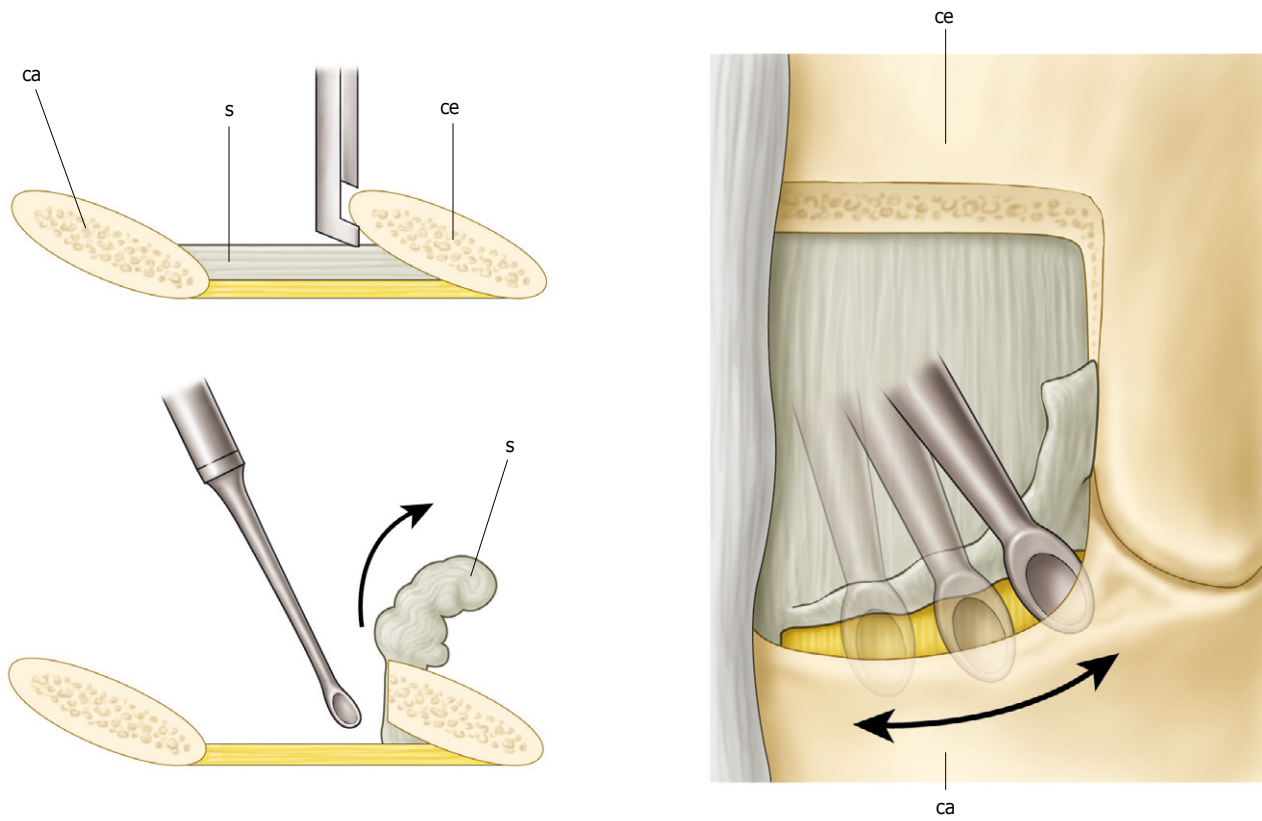
## Laminectomy and Ligamentum Flavum Dissection

Usually, the microscope is introduced into the surgical field at this stage. A hemilaminotomy is then performed with a Kerrison punch, high-speed drill or osteotome. The Kerrison punch is the most commonly used surgical instrument for this purpose. This starts from removing the inferior portion of the cephalad lamina. Removal of the lamina should end up when the midline recess of the ligamentum flavum is met. Laminectomy extends laterally until the lateral slope of the ligament is encountered (Figure 40-6). It should be borne in mind that the distance between the lateral pars borders narrows as you ascend the lumbar spine (Figure 40-7).

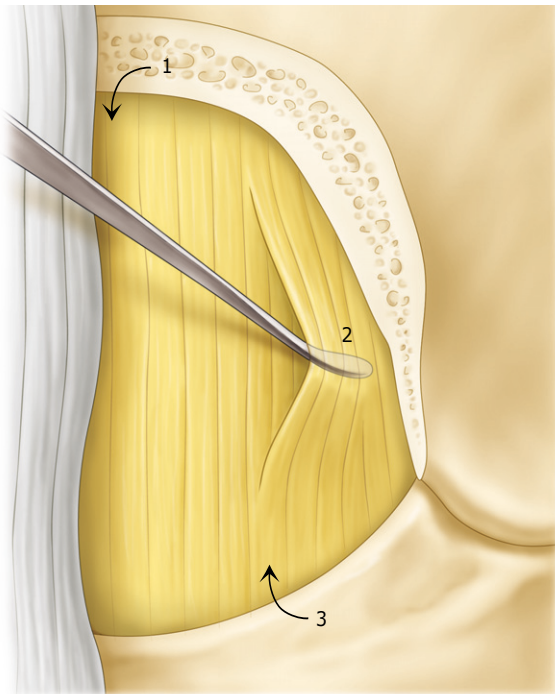
The ligament is consisted of a superficial and a deep layer. There is an inferoventral slip of the ligament that attaches to the anterosuperior surface of the caudal lamina. Although numerous methods of sparing the ligament have been described, the yellow ligament is generally removed before exploration of the epidural space. A sweeping motion of the curette over the edge of the inferior lamina facilitates thick upper layer detachment. This thinning procedure facilitates safer and easier removal of the yellow ligament (Figure 40-8). Since the layers of the facet capsule insert onto the superolateral part of the caudal lamina, a crude attempt to remove the superficial thick layer can result in injury to the capsule. There are three methods to enter the epidural space through the yellow ligament (Figure 40-9). A blunt hook is inserted into the midline recess of the yellow ligament and caudad sweep down action easily detach the ligament from its upper portion (Figure 40-10). As such, the ligament is peeled back caudally and



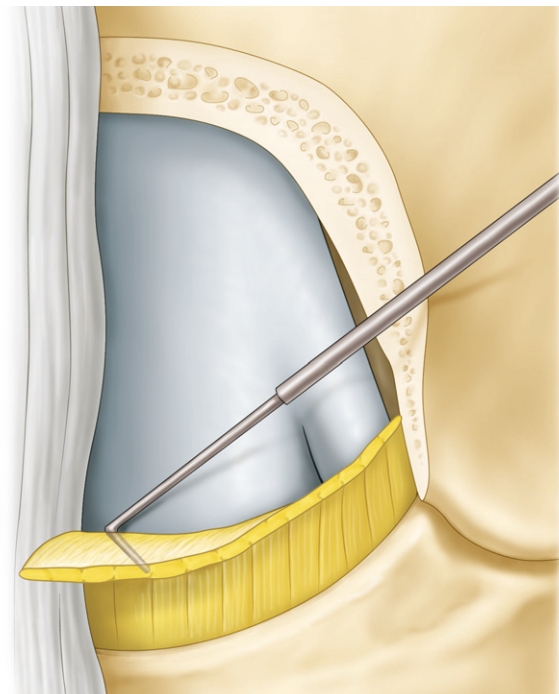
**Figure 40-7.** The width of the lamina decreases on ascending the lumbar level. In case of upper lumbar disc herniation, an unwary surgeon may get too far lateral with laminotomy and destroys the facet.



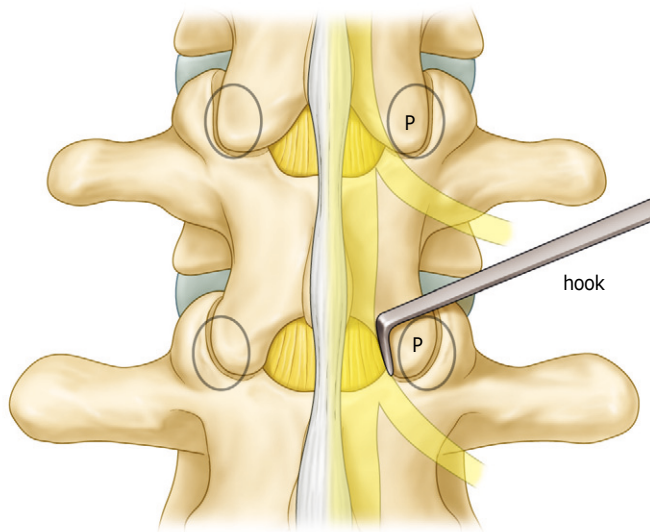
**Figure 40-8.** The thick superficial layer of the ligamentum flavum is easily removed using curette from the caudal lamina. ce. cephalad lamina; ca. caudal lamina; s. superficial layer of the yellow ligament



**Figure 40-9.** Three methods of entering the epidural space are: through the midline recess of the yellow ligament (1); peeling and dissection direct through the ligament (2) and through the caudal laminectomy site free from the ligament (3).



**Figure 40-10.** The authors' preferred method of peeling the ligament.



**Figure 40-11.** Identifying the medial wall of the pedicle using a blunt hook. p. pedicle

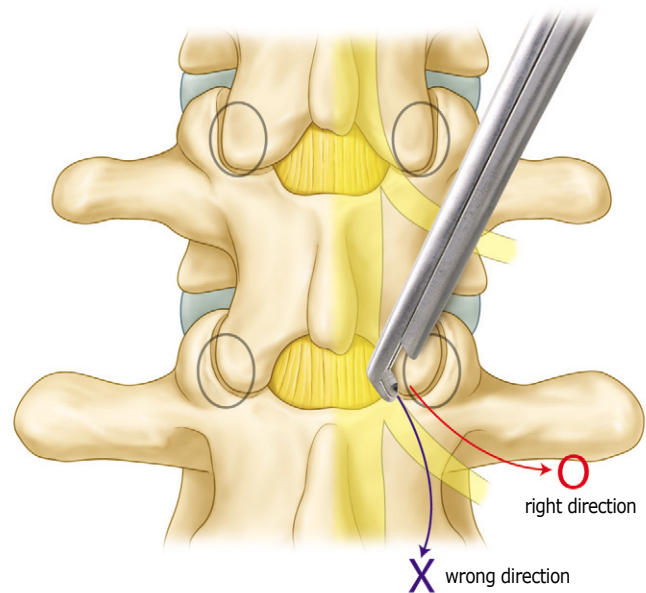
dorsally, then the remaining ligament is removed using various Kerrison punches.

After removing the caudal portion of the yellow ligament, the superior portion of the caudal lamina was removed simultaneously with the ligament. Removal of the caudal lamina should expose the medial wall of the pedicle (Figure 40-11). During ligament removal, the tip of the Kerrison punch should always head parallel to the direction of the root and the common dural sac to avoid unwanted injury to these vital structures (Figure 40-12). A general guide to the extent of ligament removal is not to stop until the lateral aspect of the traversing nerve root can be clearly visualized.

### Exploration of the Peridural Space

Since epidural fat is a natural barrier for prevention of postoperative fibrosis and adhesion, it should be preserved as much as possible, unless it hinders anatomical orientation. If necessary, epidural veins are cauterized with bipolar forceps. Using blunt nerve hook, the medial wall of the pedicle and/or the lateral aspect of the nerve root should be identified before discectomy.

The nerve root is retracted medially using a suction tube or a nerve hook. Cotton patties are also used to obtain hemostasis and/or assist retraction of the nerve root. The peridural space is thoroughly explored to ascertain the type of disc herniation precisely, and identify the location of the sequestered fragments. At this point, the surgeon should identify and distinguish the nerve root from annulus. In some cases, when the nerve root is extremely compressed, it can be easily



**Figure 40-12.** The tip of the Kerrison punch should always lie parallel or away from the dural sac or nerve root.

mistaken for a protruded annulus, or part of the yellow ligament.

### Discectomy

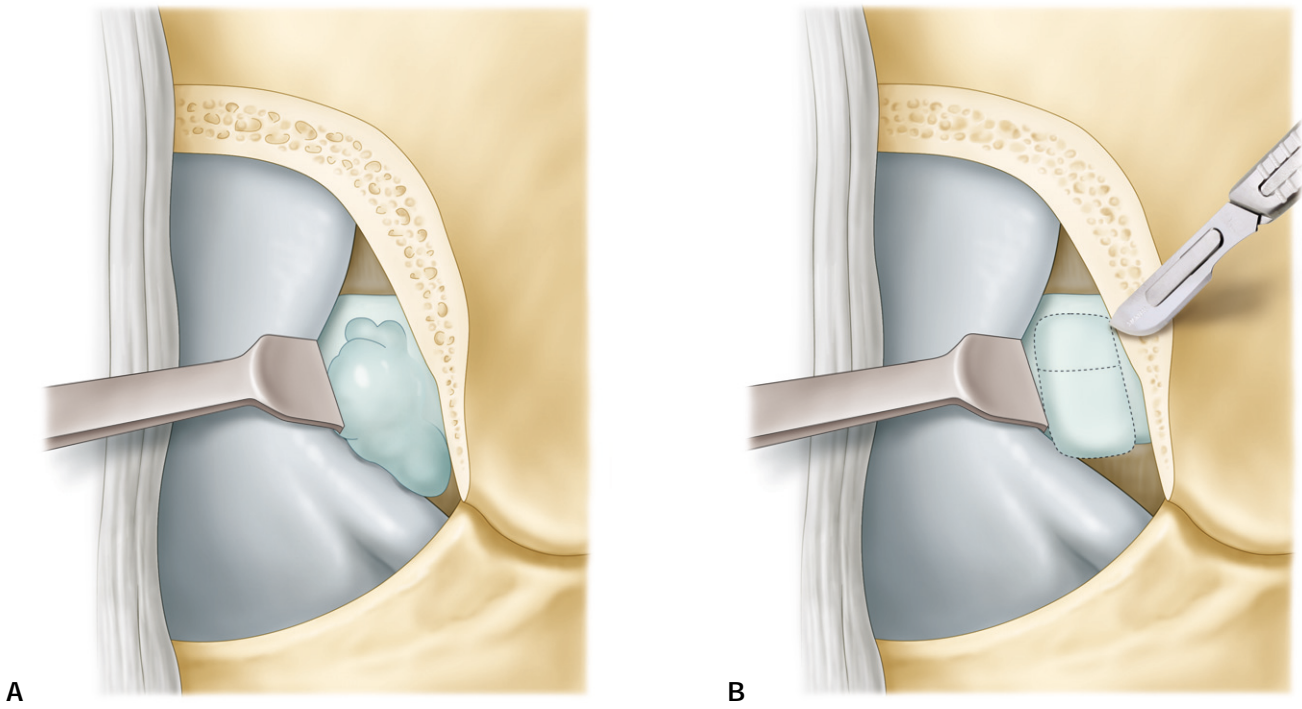
A nerve root retractor is positioned to retract nerve roots medially.

Extruded or sequestered disc fragments are easily removed by a nerve hook or pituitary rongeur. With subligamentous fragments, minimal pressure applied to a thinned annulus may cause rupture and extrusion. A huge extrusion against a root and into an axilla often requires decompression before root retraction is possible.

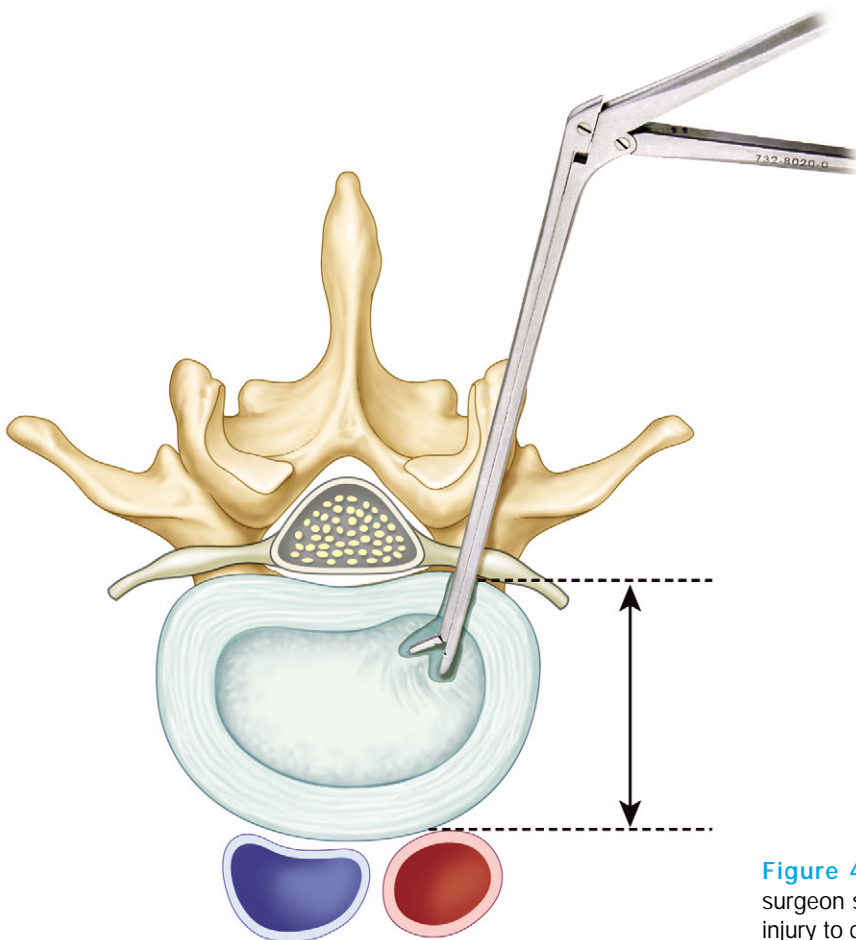
The disc space can be entered through a linear pathologic tear to a larger rectangular surgical incision (Figure 40-13). Some authors believe that a large annular excision destroys its retention wall function, which causes an increase in recurrence rate. Many authors recommend a slit-like linear incision.

If annulotomy is necessary, it is accomplished with a No. 15 blade. The herniated disc is then removed with a pituitary rongeur. The surgeon should always be aware of the depth of the inserted instrument in the intradiscal space to prevent disastrous vascular injury (Figure 40-14).

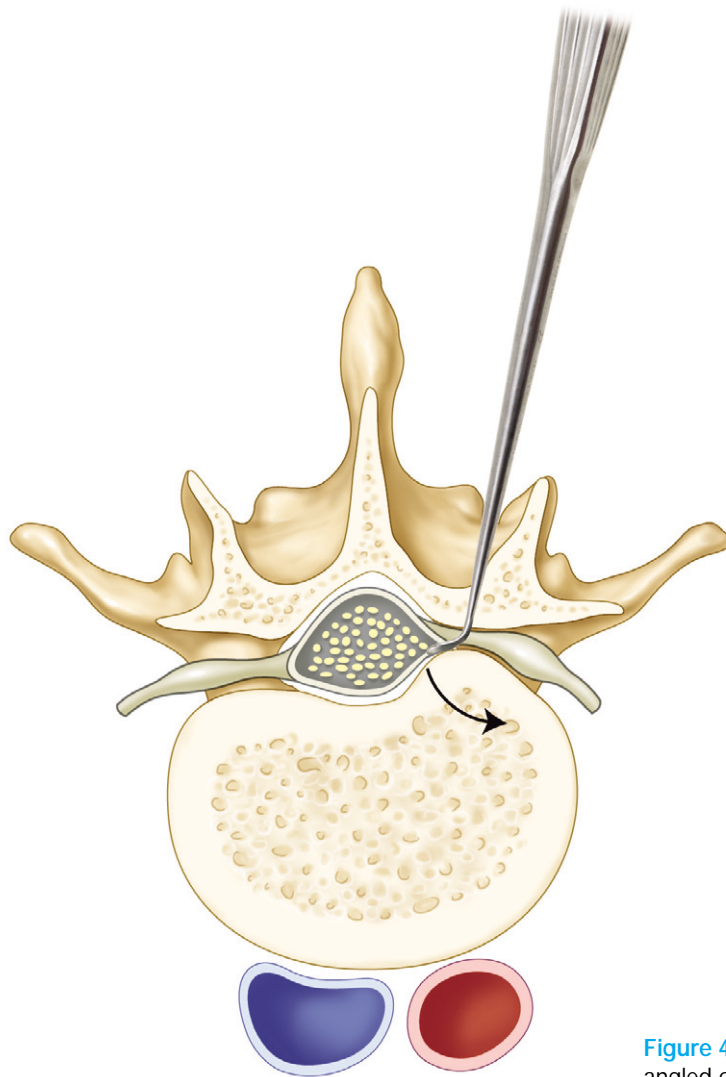
The optimal amount of disc removal is unclear. The authors routinely remove disc tissue that can be easily mobilized from the intervertebral space. Extensive disc removal is not recommended nor required. Removal of the offending pathology and intradiscal loose fragment is sufficient. The disc space is not curetted. The disc space is irrigated thoroughly following nerve root decompression. If an osteophyte is present



**Figure 40-13.** (A) An extruded disc fragment does not require annular incision. (B) The disc space can be entered through a slit to rectangular incision.



**Figure 40-14.** During the discectomy procedure, the surgeon should always have depth orientation to avoid lethal injury to great vessels.



**Figure 40-15.** An osteophyte can be removed using a reverse angled curette.

and interferes with smooth root excursion, it should be removed (Figure 40-15).

The surgeon should then perform a final inspection of the epidural space after an apparently adequate discectomy, in search of residual fragments. Several lengths of blunt nerve hooks are used to explore the peridural space and the neural foramina.

## Closure

The authors use a piece of Gelfoam® to cover interlaminar dead space. Meticulous hemostasis prevents postoperative hematoma that increases postoperative pain and the extent of epidural fibrosis. Suturing of the paravertebral muscle is not required, because it causes severe postoperative back pain. The paraspinal muscle tends to spontaneously fall back and resume their normal position. This can be assisted by the injecting lidocaine into paraspinal muscles. The authors do not routinely

use a drain. It is an option when bleeding from peridural space of concern. The fascial layer is closed with one or two interrupted absorbable sutures. The subcutaneous tissue is closed in an inverted manner. Commercially available skin tape or staple is applied to re-approximate the skin edges.

## • References •

1. EC Benzel: Spine surgery. Techniques, complication avoidance, and management. 2nd Ed. Philadelphia: Elsevier Churchill Livingstone, 601-614, 2005
2. JH Song, YK Park: Ligament-sparing Lumbar Microdiscectomy; Technical Note. Surg Neurol 53: 592-597, 2000
3. McCulloch JA and Young PH: Essentials of spinal microsurgery, Philadelphia: Lippincott-Raven, 329-382, 1998
4. YS Kim, SS Chung, KC Lee, et al: Experience with microsurgery in the herniations of lumbar, cervical, and thoracic intervertebral discs. JKNS 8: 299-305, 1979
5. YS Kim, YE Cho, DK Chin: Minimally invasive surgery in lumbar disc herniations with microendoscopic discectomy system (Technical note). JKNS 27: 177-183, 1998